Imaging in Thyroid Orbitopathy

EUGOGO
EUropean Group On Graves' Orbitopathy

Gangadhara Sundar, DO, FRCSEd, FAMS

Diplomate, The American Board of Ophthalmology
Asst Prof & Head, Orbit, Oculofacial Surgery, Ophthalmic Oncology
Singapore Society of Ophthalmic Plastic & Reconstructive Surgery (SSOPRS)
President, Asia Pacific Ophthalmic Trauma Society (APOTS)
gangadhara_sundar@nuhs.edu.sg

National University Hospital

Singapore Society of
SSOPRS
Ophthalmic Plastic & Reconstructive Surgery

EUGOGO

EUropean Group On Graves' Orbitopathy





Endocrinologists

Immunologists

NUH TED Tean











Disclaimers & Acknowledgements

- Regional & International Faculty, AOCMF International
- No commercial interest in the implants & devices

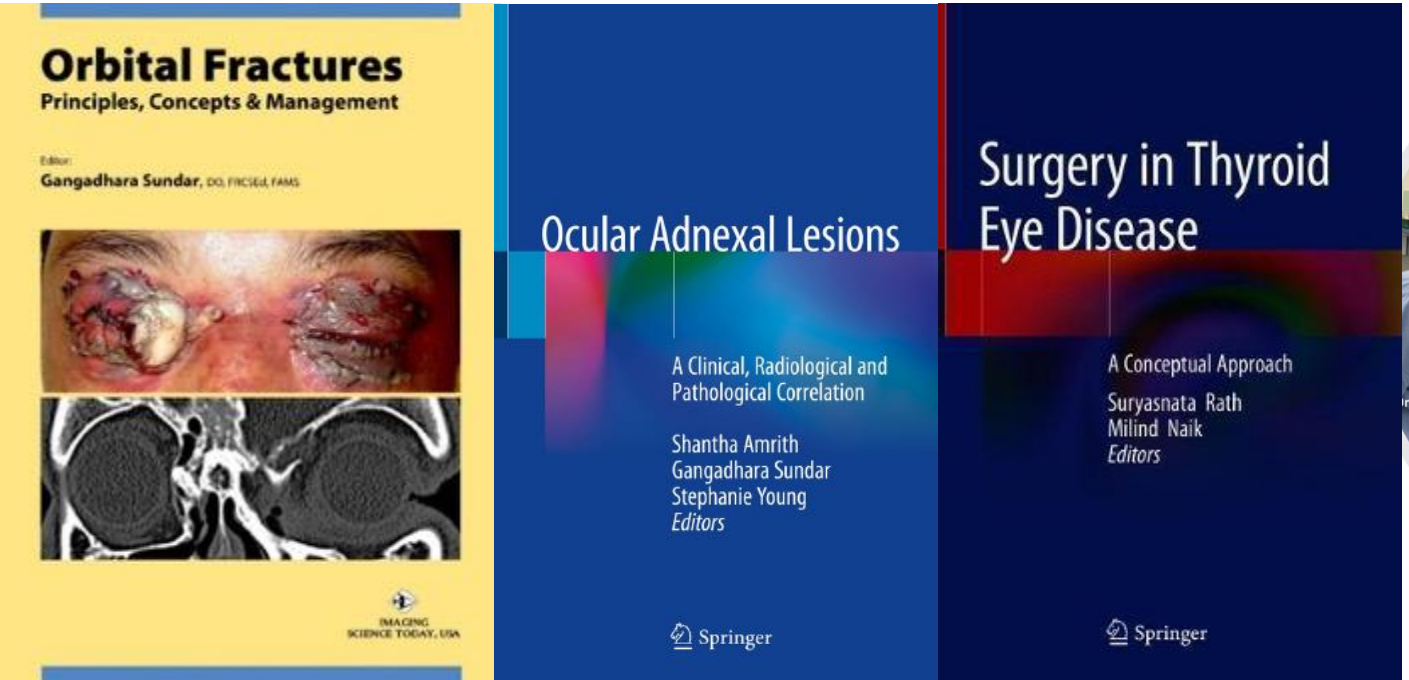



What lies underneath?







Graves Orbitopathy

Ophthalmologist
(Oculoplastic Surgeon/Strabismologist
Rhinologist)

Immunologist
Hepatologist



TED
Patient

Psychologist

Radiation
Specialist

Endocrinologist
(Medical / Surgical Endocrinologist
Nuclear medicine specialist)

IMAGING

CT Scan

MRI

Ultrasound

Octreotide scan

…

Main aims of imaging

- Confirm diagnosis
- Determine activity (MRI: STIR vs. DWI)
- Determine severity (Severe proptosis, Apical crowding, Optic nerve stretching, Globe tenting, etc)
- Planning management (bone marrow space, orbital fat, PNS, skull base)
- Post-operative verification / quality control



Indications for Imaging in TED - Diagnosis

- Beginner clinician
- Unilateral proptosis / exophthalmos (15-28%)
- Atypical presentation
- Rule out other differential diagnosis / coexisting pathology
- Patient factors*

‘SAD’
Silent Active Disease

- Validity of Clinical Activity Score (CAS)
- Caucasians vs. South Asians vs. East Asians
- Delayed diagnosis (CAS negative, no RAPD)
- High degree of suspicion
- Role of TFTs, TRAB vs. TSI





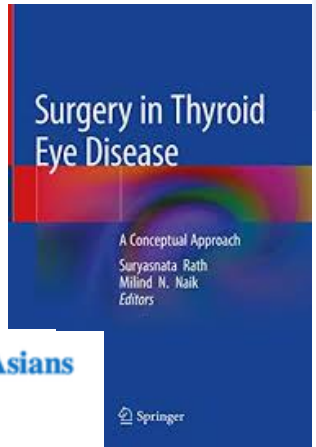

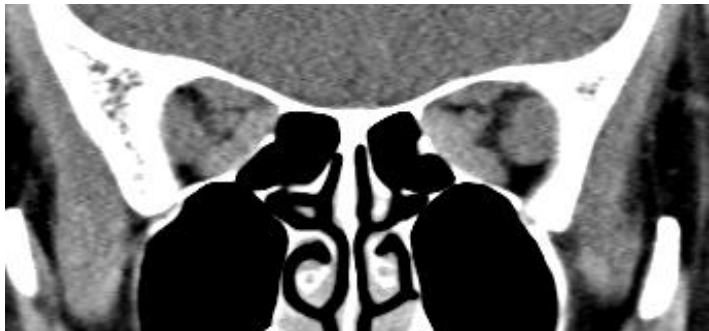

16 16 Eyelid Conditions in Thyroid Eye Disease in East Asians
Gangadhara Sundar

Indications for Imaging in TED - Management

- The compressive optic neuropathy pt
- Disease activity – equivocal (MRI STIR sequence)
- Bone vs Fat decompression planning
- Intraoperative navigation
- Assess extent of decompression postop

Imaging features in TED

Common

- EOM enlargement (tendon sparing)
- Fat volume expansion
- Apical crowding
- Bilateral symmetric disease 70%

Less common & less well known

- **Atypical EOM involvement**
- **Orbital fat – herniation, enhancement**
- **Lacrimal gland changes**
- **Vital structure lateral to the orbital apex?**
- **Variable thickness of the deep lateral wall**
- **Orbital bone remodeling**
- **Post-decompression orbital anatomy**
- **Post-decompression bone remodeling**
- **Multiple pathology**

1. CT Scans: What's well known

- Extraocular Muscle involvement > Fat involvement
- IR > MR > SR/LPS > LR > Oblique
- Fusiform enlargement
- Tendon sparing
- Bilateral & Symmetrical

I'M SLOw





Orbital tissue remodeling

- Globe displacement
  - Exophthalmometry (clinical vs radiological)
    - Inter-zygomatic line
      - Corneal vertex
      - Posterior 1/3 of globe
- Extraocular muscles
  - Recti: IR > MR > SR/LPS complex > LR*
  - Obliques???
  - Cross section vs volumetric studies
- Orbital Fat
  - Enhancement?
  - Volumetric studies
- Orbital bones

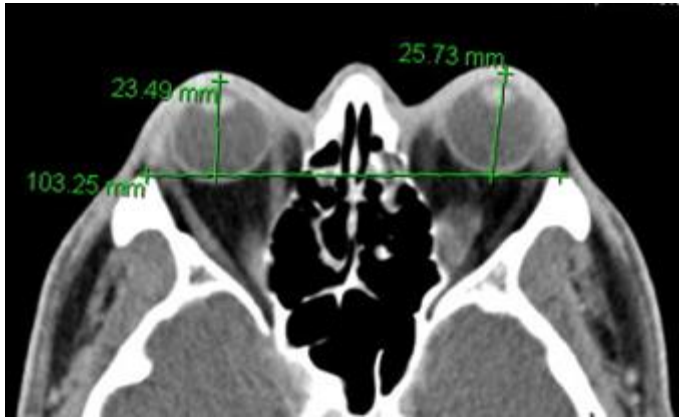

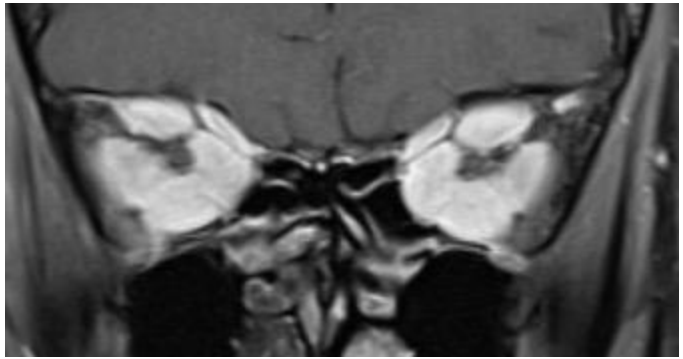

Extraocular muscles

- Recti
  - Single muscle involvement (30%) (IR vs SR!)
  - 2 muscle involvement (25%)
  - 3 muscle involvement (34%)
  - 4 muscles (21%)
  - Symmetrical involvement 70%
  - Fat lucency*
  - Volumetric studies
- Obliques
  - Superior oblique
  - Inferior oblique

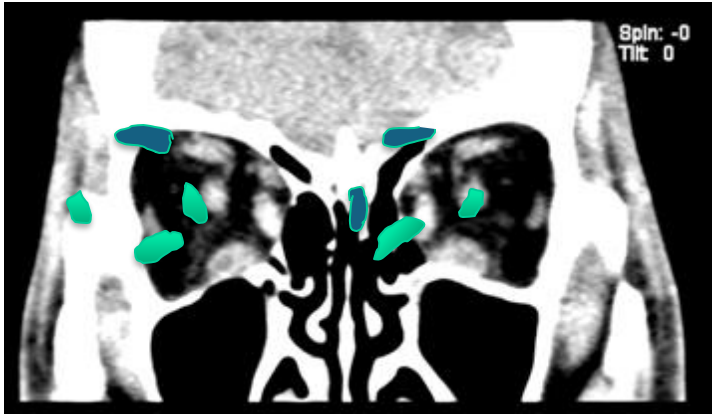

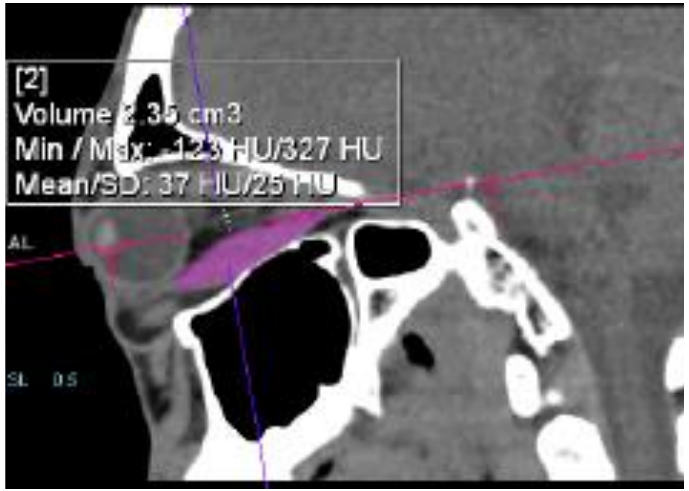

Extraocular muscles

Anterior

Mid orbit

Posterior Orbit

CT Scans

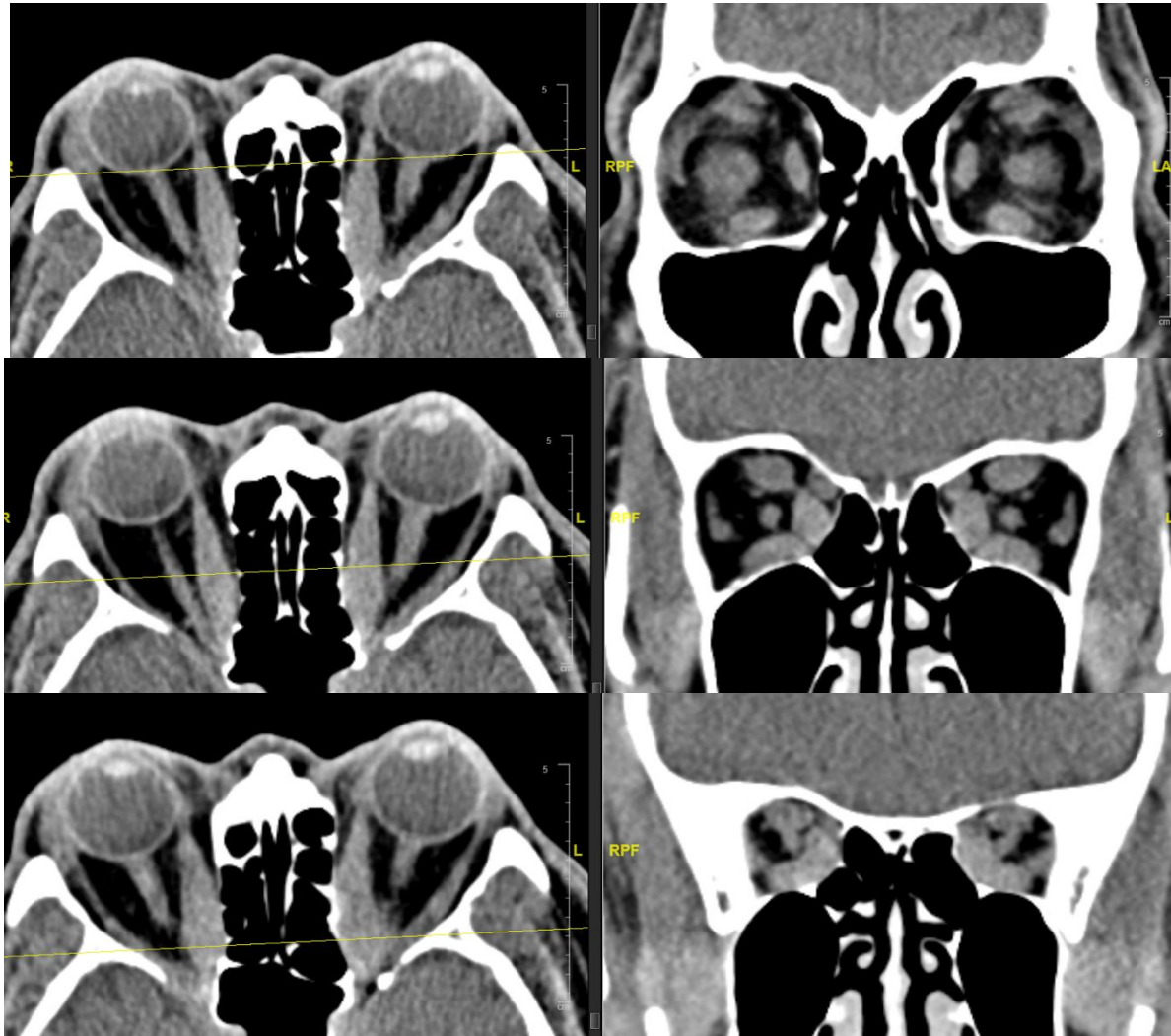

Asymmetric Atypical EOM enlargement

SIM LOw



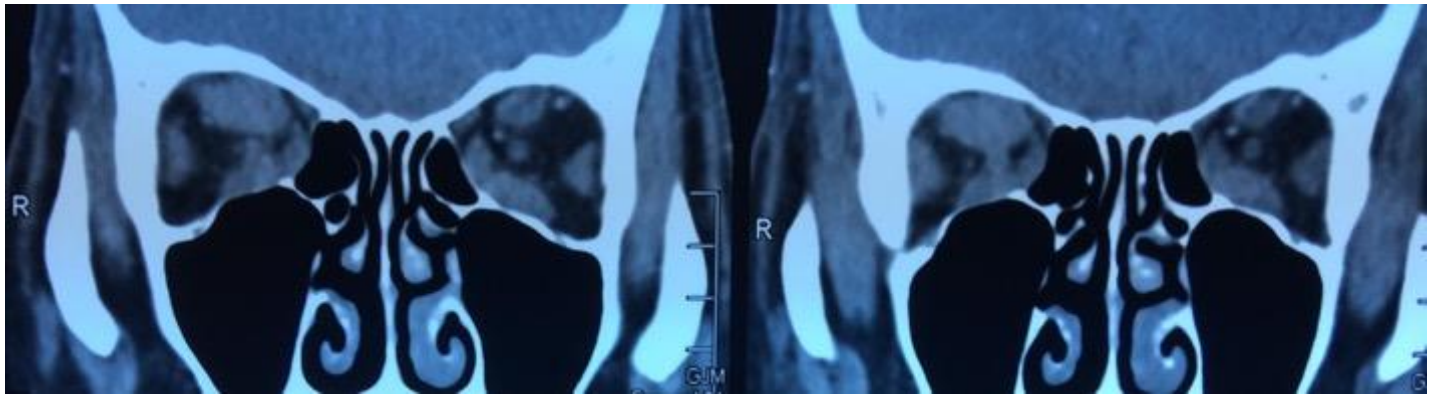





Orbital fat volume expansion (Neoadipogenesis)

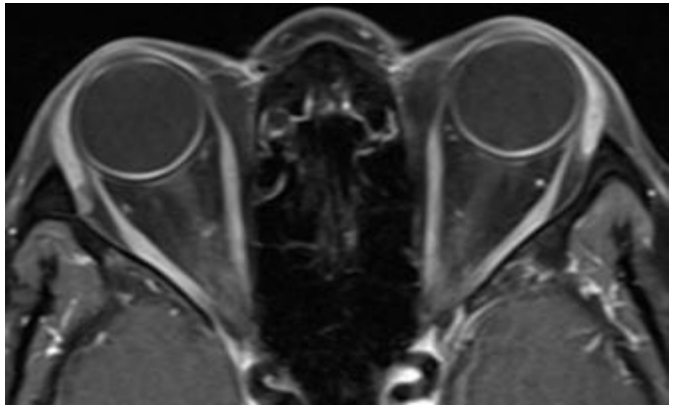

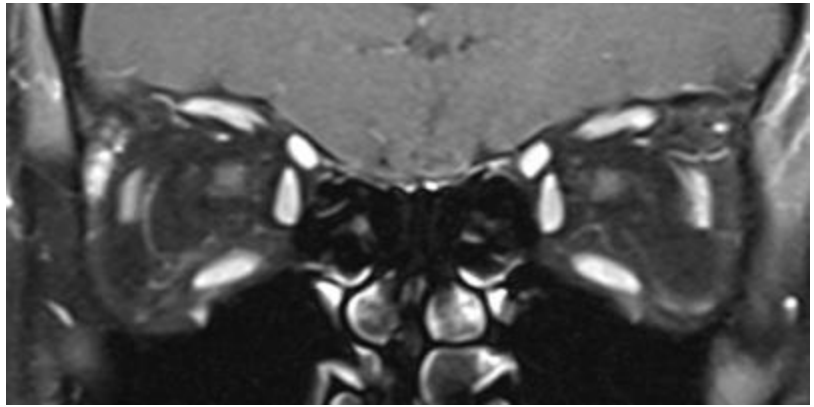

Lacrimal gland changes

- Lacrimal gland enlargement
- Lacrimal gland prolapse





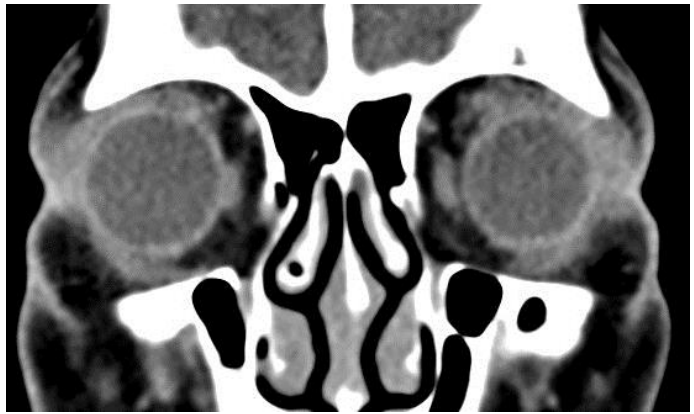

Optic Neuropathy
Compressive vs. Tractional

Compressive:

- Apical muscle crowding (88%) ≠ CON
- Perineural fat effacement*
- Optic nerve thinning? (Dodds et al)

Tractional:

- Orbital fat volume expansion with stretching
- Intracranial fat prolapse (through superior orbital fissure)

Apical crowding ≠ **Compressive optic neuropathy**

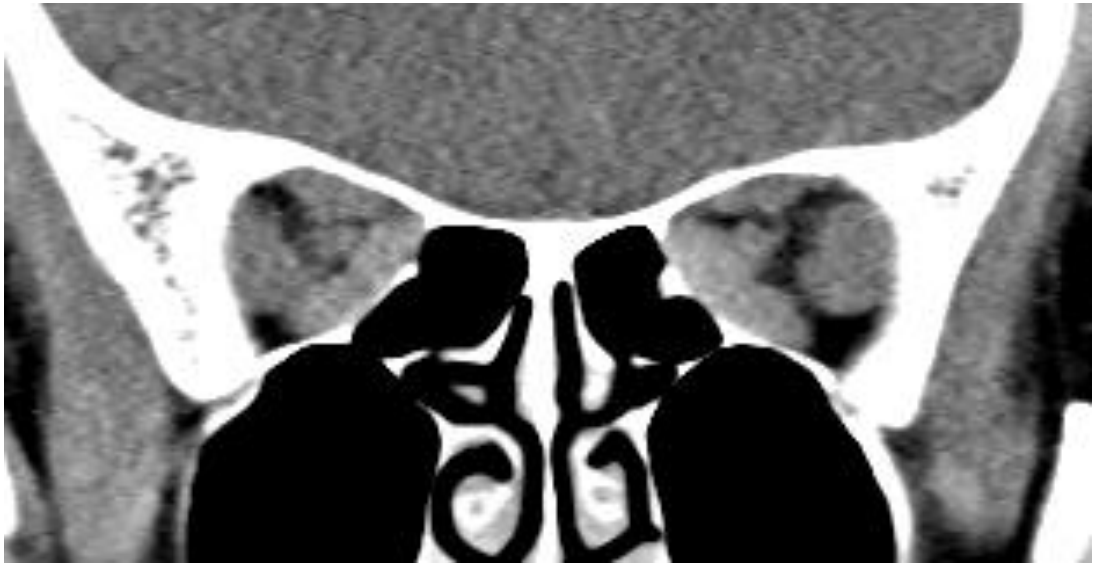

Orbital bones

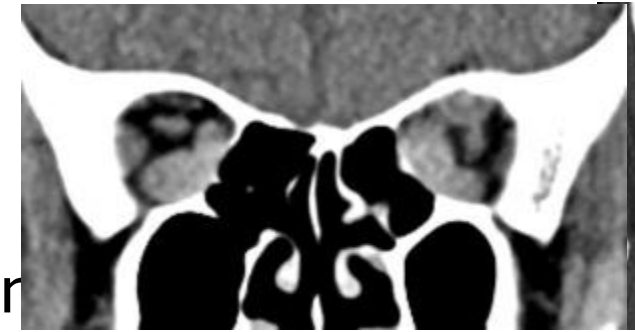

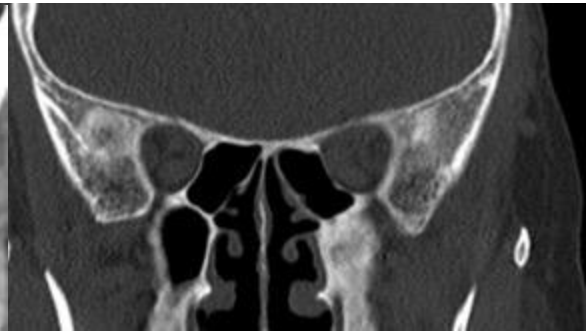

- Lateral Wall
- Medial wall remodelin
  - Angle of Medial Wall (AMW)
- Orbital strut
  - AIOS changes
- Orbital roof remodeling
- Orbital floor

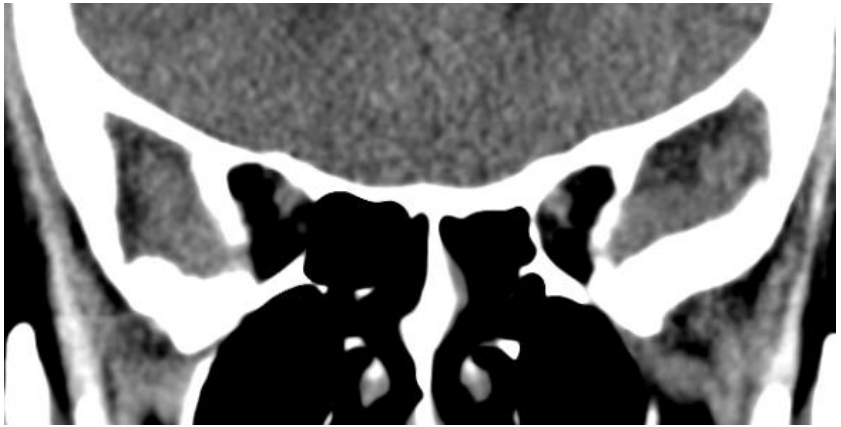

Angle of Medial Wall (AMW)

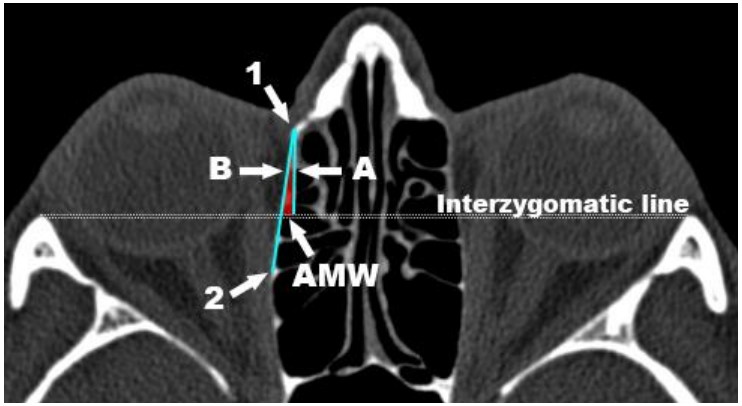

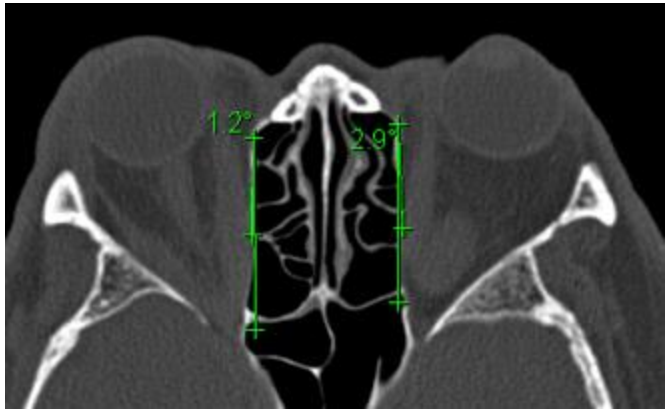

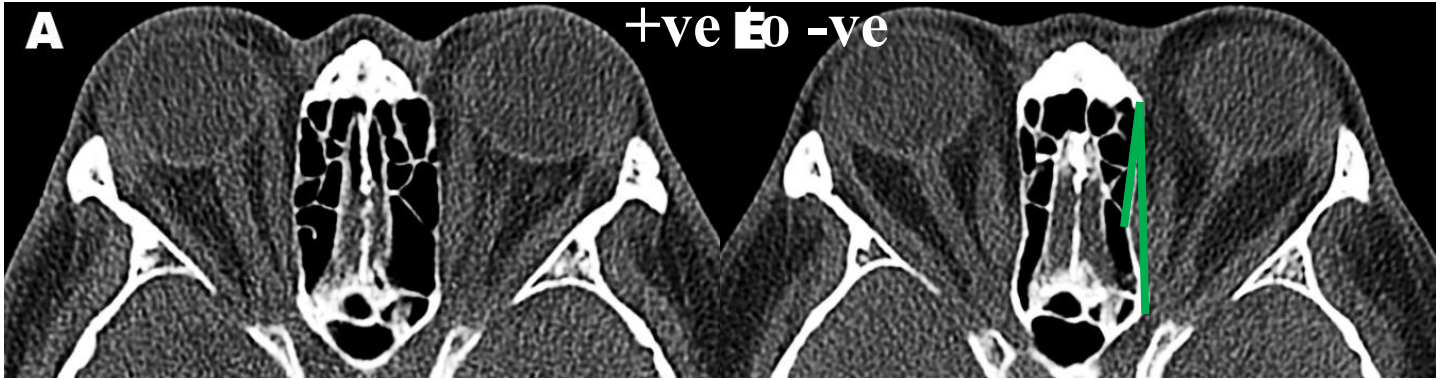

Angle of Infero-medial Orbital Strut (AIOS)

Controls TED



Clinical and Epidemiologic Research

IOVS | Month 2017 | Vol. 58 | No. 0 | 2

Radiologic Parameters of Orbital Bone Remodeling in Thyroid Eye Disease

Nicholas Y. Q. Tan,[1] Yuan-Yuh Leong,[2] Stephanie S. Lang,[3] Zin M. Htoon,[4] Stephanie M. Young,[4] and Gangadhara Sundar[4]

CT Scans in TED -Summary

- Cost effective confirmation of GO (General ophthalmologists/Developing nations)
- EOM vs. Fat vs. Bony anatomy
- Coincidental pathology
- Surgical planning
- Postoperative decompression analysis

2. Magnetic resonance imaging

Advantages

- NO ionizing radiation
- Tissue resolution
- STIR sequence: Disease activity
- ADC Values on DWI
- Baseline imaging
- Follow up imaging

Disadvantages



- Longer acquisition time
- Claustrophobia
- Poor bony assessment

MRI

- T1 (anatomy)
- T2
- T1+C (Pathology)
- Special Sequences: STIR
- DWI sequences (ADC Values)

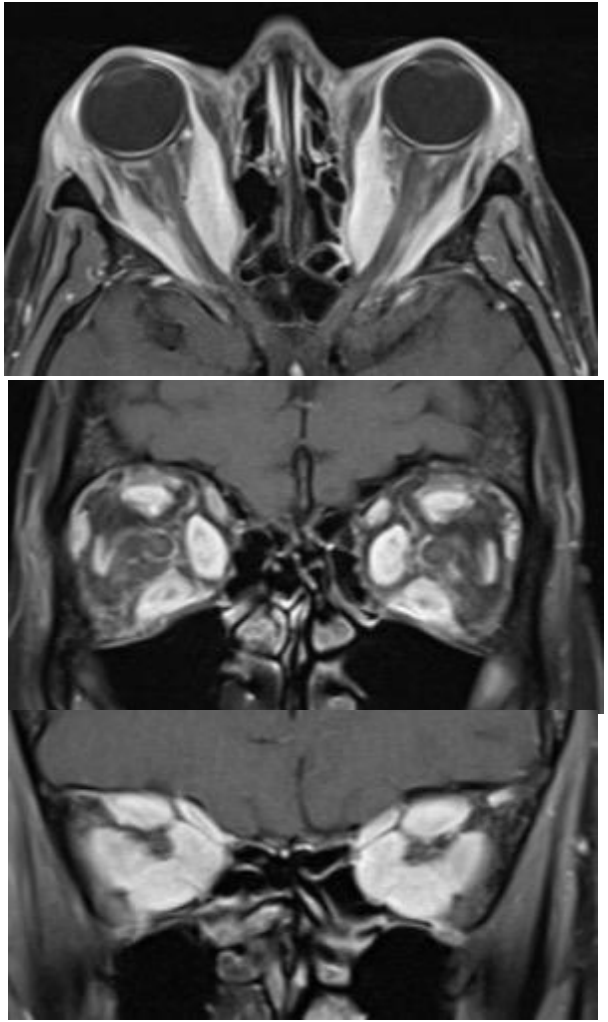

42 yr old, treated as IgG4 Related disease

(euthyroid, ‘borderline’ raised serum levels , no biopsy!!)



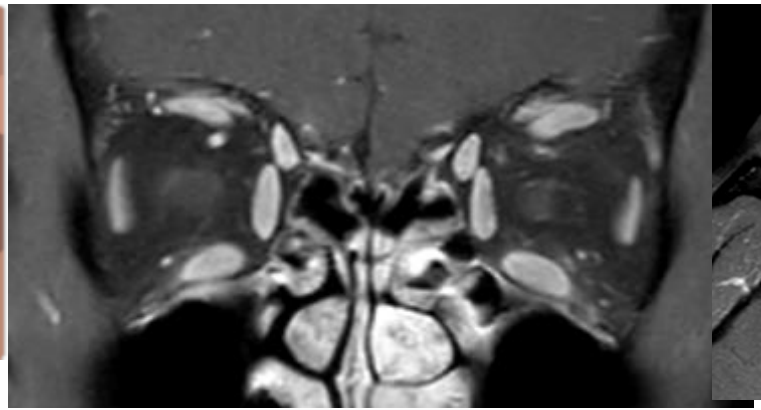



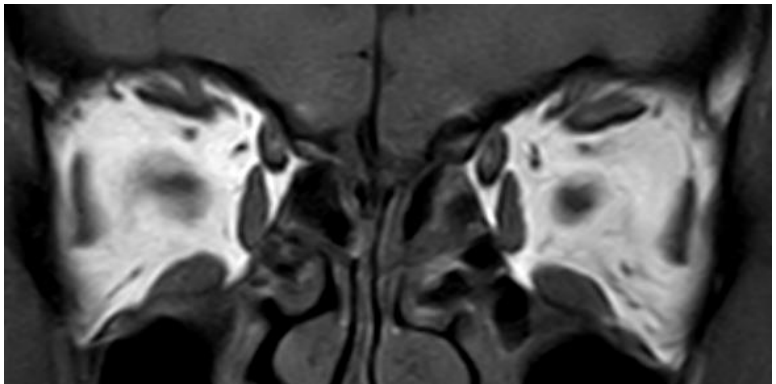

Determining Activity

- EOM enhancement (T2 hyperintensity)
- STIR Sequence ±
- ADC Values on DWI (no restriction)



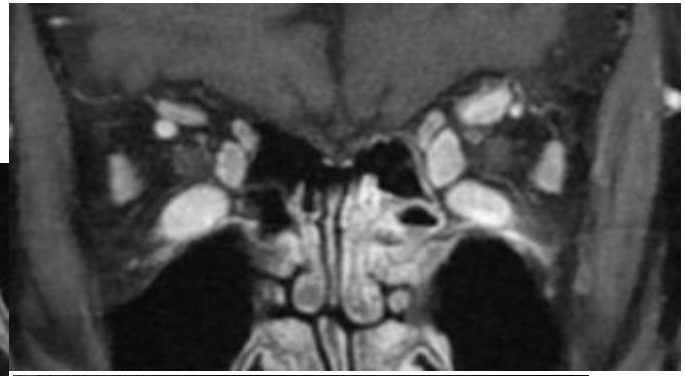



Determining Severity

- Proptosis
- Apical crowding
- Straightening optic nerve
- Globe tenting

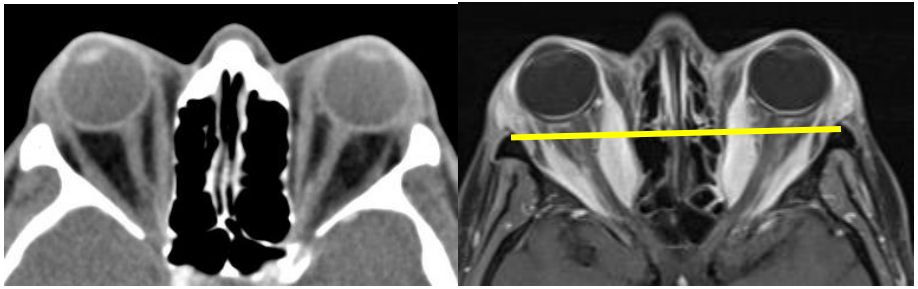

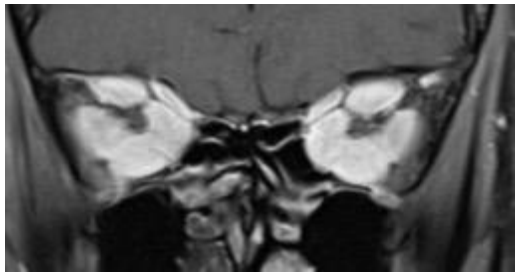

3. Others

- Value of repeat Imaging
- Incidental Findings in TED patients
- Pseudo- TED patients
- Post- decompression Imaging





Oct 2023

69-yr-old male

No comorbidities, Non-smoker

Thyroid profile normal

‘Subacute visual loss’

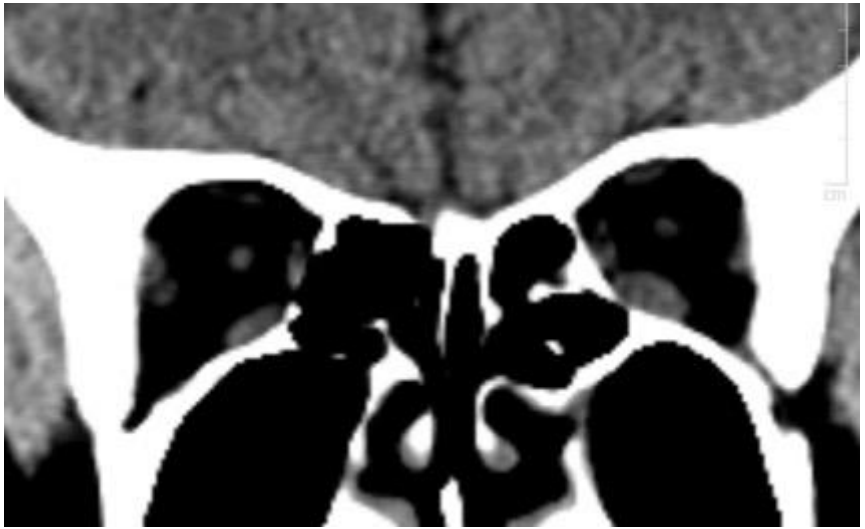

Progressive visual symtoms with Field Defects Feb 2024





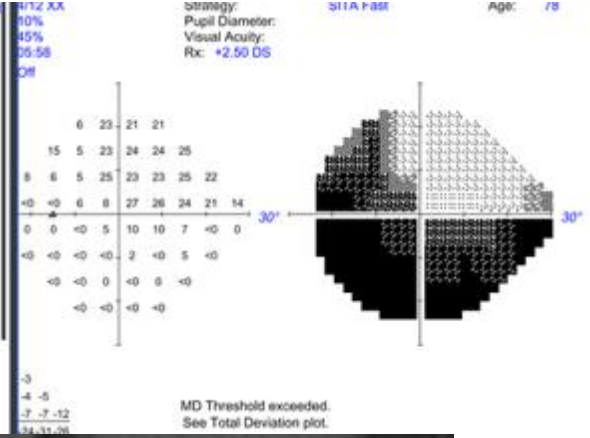





58 yr old Chinese male, non-smoker, hyperthyroidism

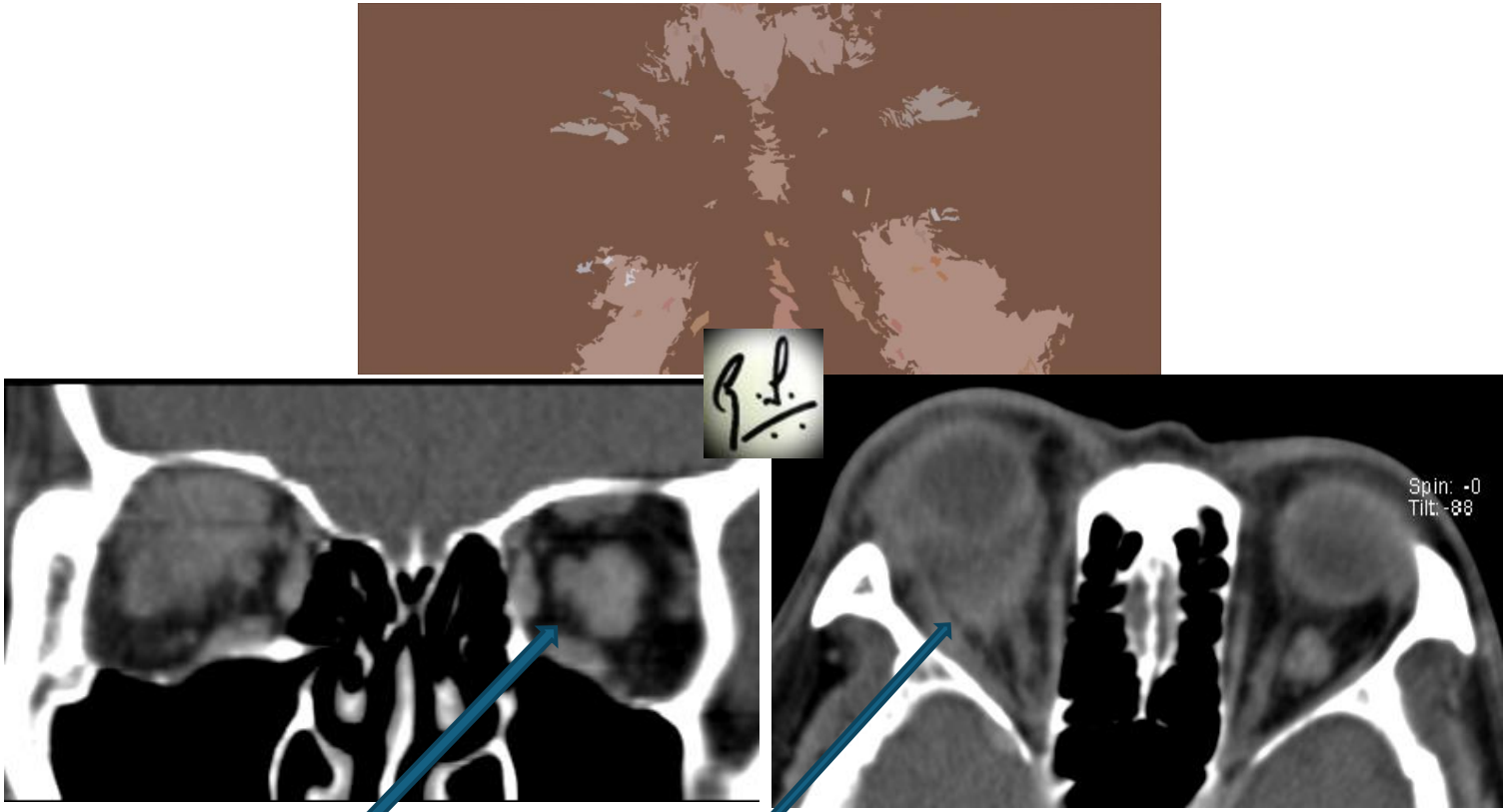

Thyroid Orbitopathy
Orbital tumor
Inflammatory Infiltrative Orbitopathy: Biopsy: Non-specific inflammation. Not Lymphoproliferative disease

69 yr old, non-smoker

St Elsewhere Hospital: ‘Epiblepharon with symptomatic Rx’





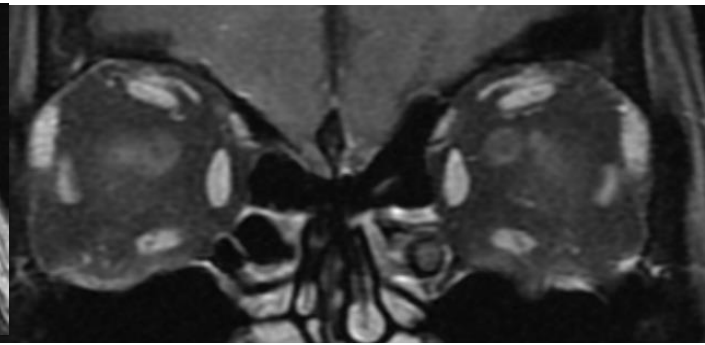

Moderate Active TED with ‘Acquired Epiblepharon ’



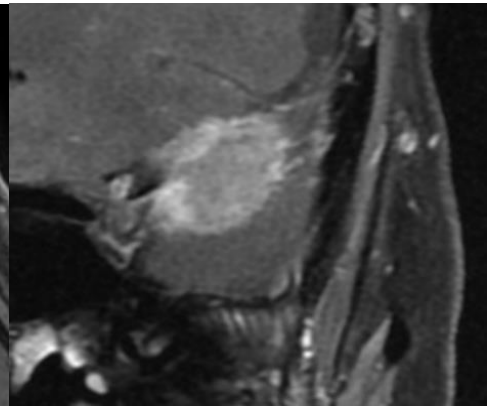

Type I TED with Sphenoid Wing Meningioma



40 yr old Chinese Female, non-smoker
Low TSH, TRAB +



‘Sphenoidal Wing Meningioma’

Value of post-decompression imaging

- Location & extent of decompression
- Intraop/Postop Complications
- Incidental findings
- Conventional vs Cone Beam CT scan

Adequacy of decompression

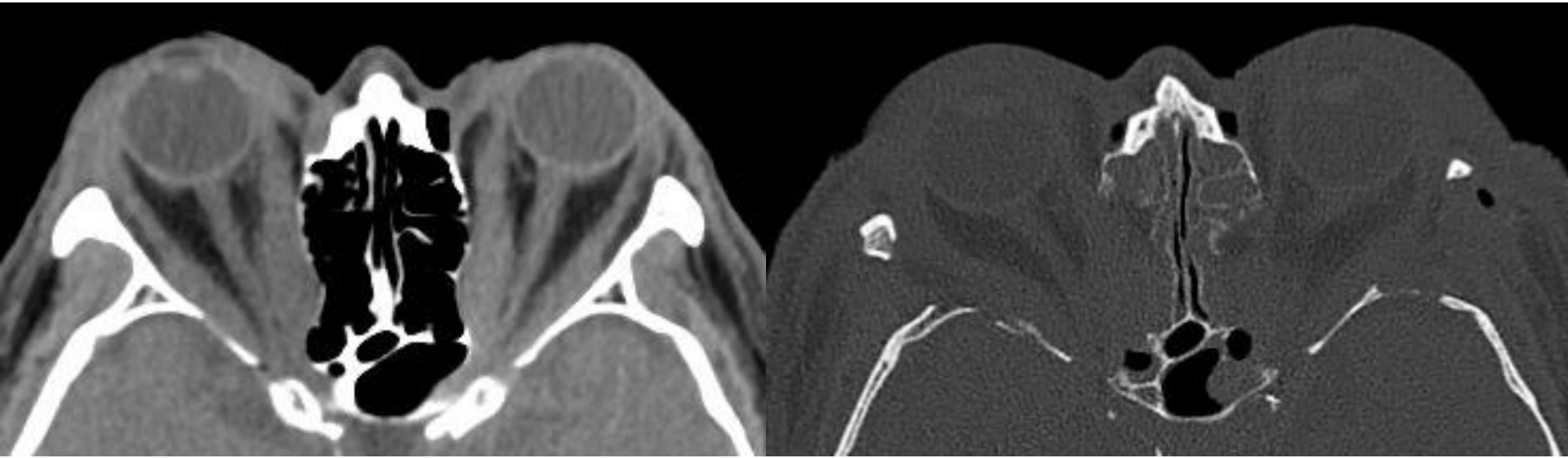

Sight Threatening TED (CON)
Pre & post ‘balanced’ decompression



Intracranial complications

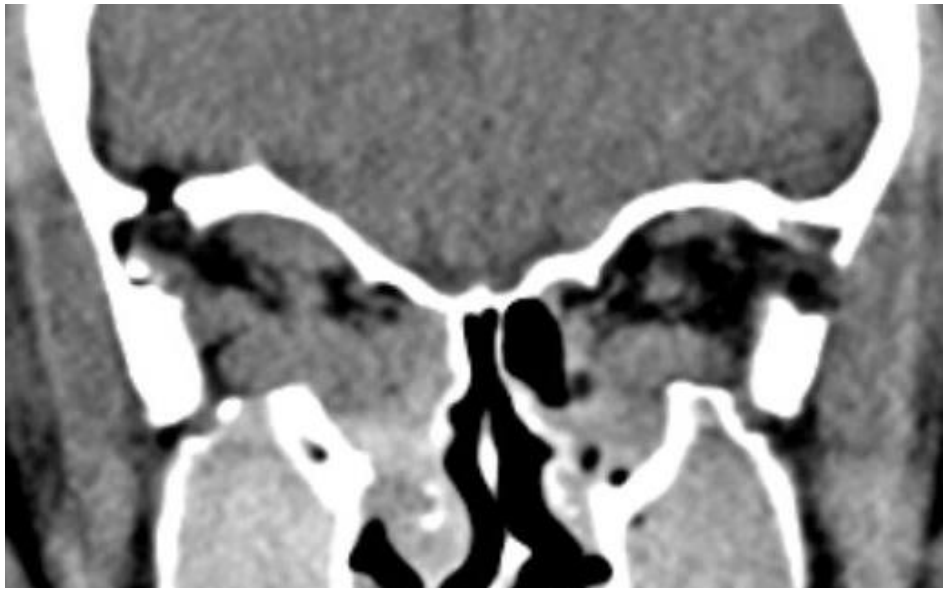



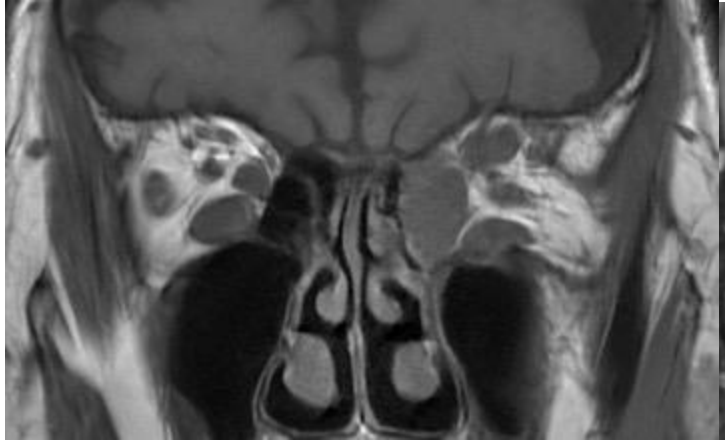

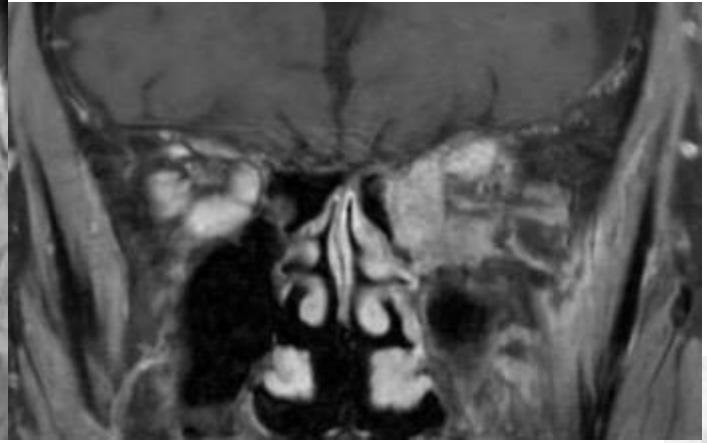

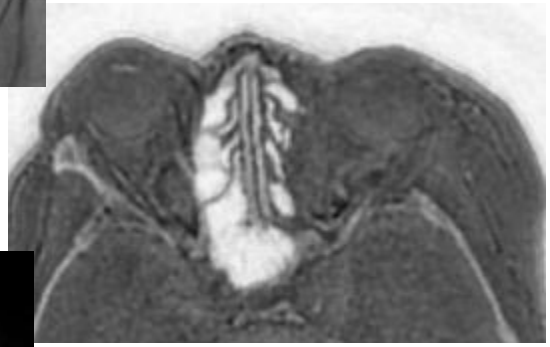

MRI Postop Imaging
(Black bone Zero TE Sequence)

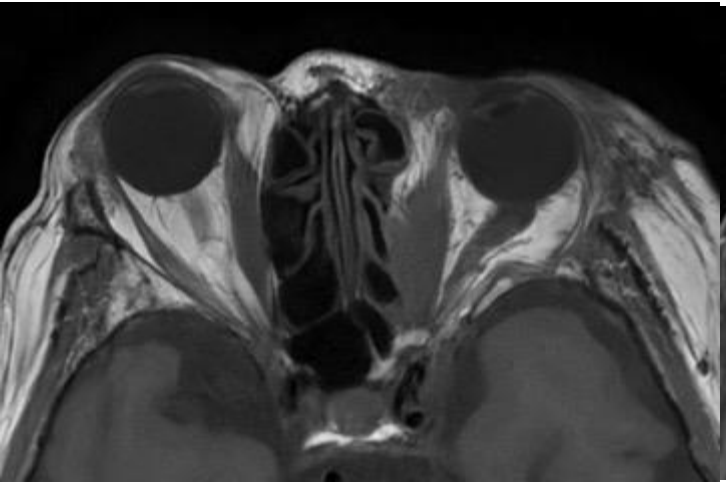

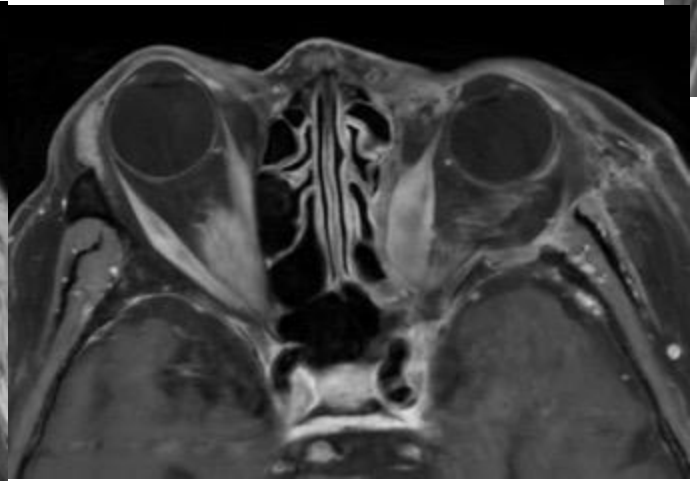

Summary

- Image, when indicated
- Diagnosis: MRI orbits, Special sequences? , Serial imaging
- Management: MRI vs. CT Scan (IGS protocol, poor man’s MRI)
- Read the Imaging - YOURSELF

Gangadhara_sundar@nuhs.edu.sg

